

Some remarks on parasitic infections of the invasive *Neogobius* spp. (Pisces) in the Hungarian reaches of the Danube River, with a description of *Goussia szekelyi* sp. n. (Apicomplexa: Eimeriidae)

By K. Molnár

Veterinary Medical Research Institute, Hungarian Academy of Sciences, Budapest, Hungary

Summary

During a survey of the parasite fauna *Neogobius* spp., which only recently invaded Hungarian reaches of the Danube River upstream from Budapest, it was found that *Neogobius melanostomus* and *N. fluviatilis* had become common species. *Neogobius kessleri* was less frequent and the previously widespread *Proterorhinus marmoratus* was drastically reduced. The parasite fauna of the newcomer fish species was characterized by ubiquitous parasites of a wide host range, such as the trematode *Nicolla skrjabini*, the metacercariae of *Metagonimus yokogawai* and *Apatemon cobitidis*, the larval stages of the acanthocephalan *Pomphorhynchus laevis* and the nematode *Rhaphidascaris acus*, the glochidia of an *Anodonta* sp. (Mollusca) and the ciliophoran *Ichthyophthirius multifiliis*. The specific parasites of *Neogobius* spp. were represented by three intestinal coccidia: *Eimeria daviesae*, *Goussia kessleri*, and a new species described here as *Goussia szekelyi* sp. n. This survey showed that the rapid invasion of Ponto-Caspian gobies in the northern Danube caused important changes in the fish fauna composition of the Danube River and enriched the parasite fauna of Hungarian fishes.

Introduction

Members of the speciose family Gobiidae are generally inhabitants of the coastal zones of seas, brackish waters and reaches of rivers close to the sea. However, numerous species belonging to this family inhabit freshwaters far from the sea. Over a long period of time only a single gobiid species, the tubenose goby [*Proterorhinus marmoratus* (Pallas)] was known to occur in Hungary. This species was first detected in 1872 by Kriesch (cit. Pintér, 1989) in a creek flowing into the Danube River. The river goby [*Neogobius fluviatilis* (Pallas)] was first found in Lake Balaton in 1971 (Bíró, 1972), but was recorded from the Hungarian reaches of the Danube River only in 1984 (cit. Pintér, 1989). Occurrence of the bighead goby [*Neogobius kessleri* (Günther)] in this region was first reported by Erős and Guti (1997). While sampling fish in the Danube reaches upstream from Budapest, Molnár and Baska (1998) also observed the frequent occurrence of the bighead goby but were able to sample only some rare specimens of the tubenose goby, although this latter fish had earlier been one of the most common fish species in the Danube. Some years later Guti (1999) and Guti et al. (2003) reported two additional species, the Syrman goby [*Neogobius syrmani* (Nordmann)] and the round goby [*Neogobius melanostomus* (Pallas)], respectively.

Ahnelt et al. (1998) and Holčík et al. (2003) explained the rapid expansion of *Neogobius* spp. in the Danube by the passive transmission of fishes or their eggs in the ballast water of ships. The introduction and spread of *G. melanostomus* and *P. marmoratus* in Canada and the USA (Jude et al., 1992; Vanderploeg et al., 2002; Philips et al., 2003; Corcum et al., 2004) as well as in the Baltic Sea (Sapota, 2004) were attributed to the same mode of transmission.

The Russian literature contains abundant data on the parasites of gobiid fishes (Bykhovskaya-Pavlovskaya et al., 1962; Naidenova, 1974). The parasite fauna of migrating *Neogobius* species in Europe were studied by Molnár and Baska (1998) and Koubková and Baruš (2000). Muzzal et al. (1995); Pronin et al. (1997) and Camp et al. (1999) surveyed the parasitic infections of the introduced tubenose goby and round goby in North America.

Relatively little is known about the coccidian parasites of gobiid fishes. Known species include *Eimeria gobii* from *Gobius medius* and *E. glossogobii* from *Glossogobius giuris*. *Eimeria variabilis* (Thélohan, 1893), common in cottid fishes, has also been recorded in *Gobius bicolor* and *G. paganellus* (Dyková and Lom, 1983). Moshu (1992) described *E. credintsi* from the freshwater tubenose goby in Moldavia. Another coccidium, *E. marmorata*, was recorded by Molnár (1996) from the latter fish species. Two other species, *Goussia kessleri* and *Eimeria daviesae*, were described by Molnár (2000) from the bighead goby.

The original purpose of this survey was to study the parasite fauna of the tubenose goby and the bighead goby. The study on the interaction between the original and the newcomer fish species began when a decrease in the occurrence of the tubenose goby was observed. In this paper data are reported on the parasite fauna of three *Neogobius* species, including the description of *Goussia szekelyi* sp. n. and changes in the composition of gobiid fauna in the Danube River.

Materials and methods

In order to survey the parasite fauna of Danube fishes, collections were made on a regular basis between 1989 and 2004. Fish were collected with the help of an electrofishery device or, less frequently, with a closed-mesh net in reaches of the Danube River to the north of Budapest at the mouth of the Bükkös Creek. With few exceptions, gobies could only be caught with the electric device. During the above period 105 tubenose goby (*Proterorhinus marmoratus*), 101 bighead goby (*Gobius kessleri*), 50 river goby (*G. fluviatilis*) and 63 round goby (*G. melanostomus*) measuring 3–15 cm were transported live to

the laboratory in oxygen-filled plastic bags and kept in an aquarium for 1–2 days, killed by decapitation and subjected to complete parasitological examination. To detect coccidian infection, fresh mucus from the intestinal tract was examined for the presence of oocysts. Drawings of sporulated oocysts were made and measurements were taken using an Olympus interference contrast microscope (Olympus Optical Co. Ltd, Tokyo, Japan) immediately after the oocysts had been detected or when sporulation had been completed. Unsporulated oocysts were placed in small Petri dishes filled with room temperature tap water and allowed to sporulate. To prevent excessive proliferation of bacteria, a few micrograms of penicillin were added. In some cases, mucus in tap water that contained unsporulated oocysts was placed in an Eppendorf tube, allowed to sink to the bottom of a large dish and kept under flowing tap water. For histological examination, guts harbouring only unsporulated oocysts of the new coccidian species were fixed in Bouin's solution. The fixed material was embedded in paraffin wax and serially sectioned. The 4 µm thick sections were stained with haematoxylin and eosin. Fresh preparations and histological sections were photographed with an Olympus DP 10 digital camera (Olympus Optical Co. Ltd, Tokyo, Japan) mounted on an Olympus BH-2 microscope.

Results

Between 1989 and 1997 only tubenose gobies (82 specimens) were collected. The bighead goby was first found in 1998; at that time the catch was composed of 86 bighead gobies and 17 tubenose gobies. In 1999 six bighead gobies and six tubenose gobies were collected. From 2000 to 2003, when only closed-mesh nets were used for seining cyprinid fishes, only a single bighead goby was caught. In July, August, and October 2004, when an electric device was used for collection, 50 river gobies, 63 round gobies and eight bighead gobies were caught. At the same time the tubenose goby was not found in the catch of this Danube stretch, although some years earlier this fish had been rather frequent.

Nine known parasite species and one new parasite species, to be described as *Goussia szekelyi* n. sp., were detected in the invasive *Neogobius* species.

Parasites common in Danube fishes or known from previous studies on gobiids

Trematoda:

Nicolla skrjabini (Iwanitzky, 1928); intestine
Hosts: *Neogobius fluviatilis* (25 = 50%), *N. kessleri* (46 = 46%), *N. melanostomus* (45 = 71%)

Metagonimus yokogawai Katsurada, 1912 metacercaria; scales
Hosts: *Neogobius fluviatilis* (50 = 100%), *N. kessleri* (101 = 100%), *N. melanostomus* (63 = 100%)

Apatemon cobitidis (Linstow, 1980) metacercaria; abdominal cavity
Hosts: *Neogobius fluviatilis* (1 = 2%), *N. kessleri* (9 = 9%), *N. melanostomus* (3 = 7%)

Acanthocephala:

Pomphorhynchus laevis (Müller, 1776) acantella; abdominal cavity
Hosts: *Neogobius fluviatilis* (49 = 98%), *N. kessleri* (99 = 98%), *N. melanostomus* (59 = 93%)

Nematoda:

Raphidascaris acus (Bloch, 1779) larva; intestinal serosa
Host: *Neogobius fluviatilis* (3 = 6%)

Mollusca:

Anodonta sp. glochidium; fins
Host: *N. melanostomus* (6 = 9%)

Ciliophora:

Ichthyophthirius multifiliis Fouquet, 1876; gills
Hosts: *Neogobius fluviatilis* (2 = 4%), *N. kessleri* (10 = 10%), *N. melanostomus* (6 = 10%)

Apicomplexa:

Eimeria daviesae Molnár, 2000; intestine
Hosts: *Neogobius fluviatilis* (5 = 10%), *N. kessleri* (53 = 52%)

Goussia kessleri Molnár, 2000; intestine
Hosts: *Neogobius fluviatilis* (34 = 68%), *N. kessleri* (64 = 65%), *N. melanostomus* (29 = 46%)

Goussia szekelyi n. sp.; intestine
Hosts: *Neogobius melanostomus* (30 = 47%), *N. fluviatilis* (22 = 45%)

Description of *Goussia szekelyi* n. sp. (Fig. 1)

Type host: *Neogobius melanostomus* (Pallas); Gobiidae

Additional host: *Neogobius fluviatilis* (Pallas)

Type locality: Danube River upstream from Budapest

Site: Mucus and epithelium of the foregut

Prevalence of infection: 33% in the type host; 33% in river goby and 11% in the bighead goby.

Intensity of infection: Four to eight oocysts in the mucus. Four to ten oocysts per microscopic fields at 200× magnification in the epithelium of the foregut in histological sections.

Type-material: Phototypes and histological sections have been deposited in the parasitological collection of the Hungarian Natural History Museum, Budapest. Coll. No. HNHM-17627 and 17628

Etymology: The species is named in honour of Dr Csaba Székely, who first called the author's attention to the coccidian infection of *N. fluviatilis*.

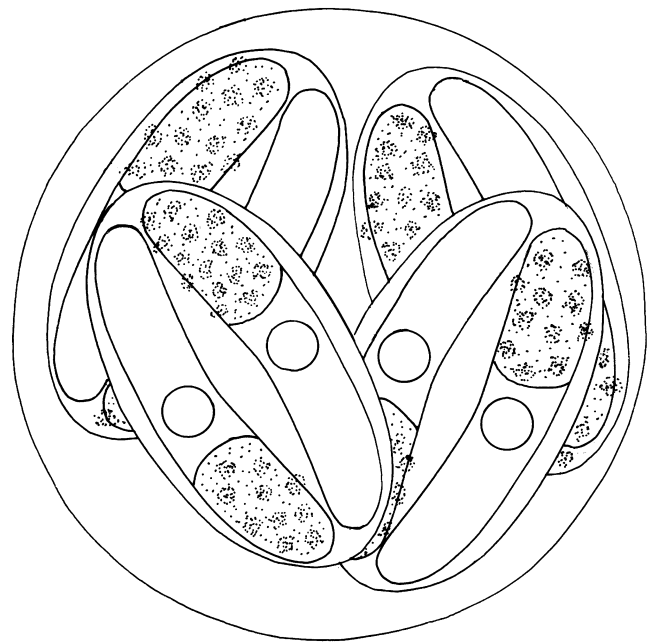


Fig. 1. Schematic drawing of the oocyst of *Goussia szekelyi* n. sp. Bar = 10 µm

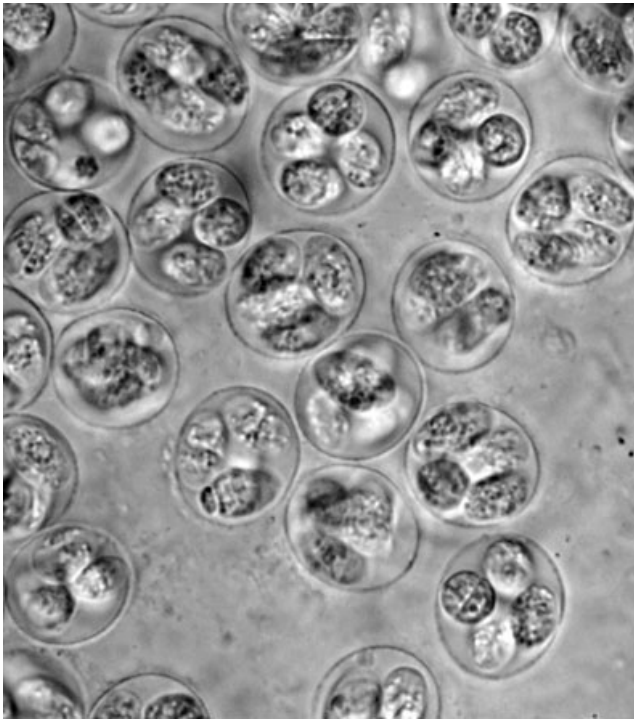


Fig. 2. Semisporulated oocysts of *Goussia szekelyi* n. sp. in the mucus from the gut of *Neogobius melanostomus*. The sporozoites in the sporocysts are hidden by the roughly granulated sporocyst residua. $\times 660$

Description (based upon 25 sporulated oocysts). All measurements are given in μm .

Sporulated oocysts (Figs 1 and 2) spherical 14–15.5 (14.7 ± 0.59) or short ellipsoidal $13.8\text{--}16.7 \times 13.1\text{--}15.2$ ($15.7 \pm 0.77 \times 14.1 \pm 0.65$). Wall of the oocyst thin, smooth, colourless. Micropyle, polar granule and oocyst residuum absent. Oocysts contain four ellipsoid sporocysts, which fill the oocyst space relatively loosely and are arranged in most cases in different directions so that in one plane three sporocysts can be seen. Size of sporocysts $9.3\text{--}11.7 \times 4.9\text{--}6.6$ ($10.2 \pm 0.8 \times 5.8 \pm 0.44$). Sporocyst wall thin, single layered. The two sporocyst valves are connected by an indistinct, longitudinally running suture. Stieda-body or Stieda-body-like structure is not seen. Sporozoites banana shaped, located head to tail in the sporocyst and measuring $8.0\text{--}9.3 \times 2.3\text{--}3.0$ ($8.7 \pm 0.43 \times 2.5 \pm 0.44$). Sporocyst residuum small, rough scattered dots ($0.8\text{--}1.2$) arranged in the sporocyst on opposite sides, partially obscuring the sporozoites.

Oocysts passed from the gut unsporulated. Unsporulated oocysts round or short ellipsoidal finely granulated bodies (Fig. 3a). Round oocysts measured 13–14.5 (14) in diameter; short ellipsoidal oocysts measured $13\text{--}14 \times 14.5\text{--}15.7$ (13.3×15.4). Oocyst sporulation was successful both in small Petri dishes under antibiotic protection and in large volumes of refreshed tap water. Whereas in Petri dishes the oocyst sporulation ceased after 48 h, sporulation was continuous in flowing tap water in which the oocysts retained their viability for long periods.

After 12 h of sporulation in tap water at 24°C , a space appeared between the wall of the oocysts and the sporont, and the size of the oocysts increased. Four elliptical sporocysts were formed and filled by scattered, roughly granulated residual bodies (Fig. 2). At 24 h of sporulation the banana-shaped sporozoites covered by the residual granules were

recognizable. After 48 h of sporulation the sporocyst residuum, composed of some rough granules, was concentrated at the blunt end of the sporozoites (Fig. 3b) in which a large refractile body was located (Fig. 3c). After 72 h of sporulation the number of sporocyst granules decreased and the banana-shaped sporozoites were clearly seen. In ageing oocysts the sporocyst residuum was composed of some rough granules. The sporocysts became shorter and pyriform in shape. In some sporocysts the sporozoites were rounded and located at opposite ends of the sporocysts (Fig. 3d).

Histology

Besides young trophonts, only macrogamonts and microgamonts were found in histological sections. The infection was mostly restricted to the midgut region. Gamonts were located in the apical cytoplasm of the enterocytes (Figs 4 and 5). Young trophonts (Figs 4 and 5) stained intensively with haematoxylin. Mature macrogamonts (Fig. 4) had a dark-staining wall and a nucleus surrounded by a pale-staining plasm. Dot-like microgametes (Fig. 6) stained intensively in the young microgamonts. Mature microgamonts (Fig. 5), were filled by comma-shaped gametes. Both macro- and microgamonts were spherical and about the same size (12.5–13.5 in diameter). No striking pathological changes were observed, but the continuity of the epithelial lining was more frequently damaged in infected regions than in uninfected areas. The epithelial lining was ruptured in areas where unsporulated oocysts were released from the epithelium (Fig. 7).

Remarks: In the size of the oocysts and morphology of the sporocysts this species resembled the epicellular type coccidia (*G. pannonica* Molnár, 1989; *G. janae* Lukes and Dyková, 1990; *G. desseri* Molnár, 1996), but also differed because oocysts of *G. szekelyi* sp. n. develop intraplasmally in enterocytes. Both *G. szekelyi* sp. n. and the above listed epicellular coccidia left the fish unsporulated, but sporocysts of *G. szekelyi* in the sporulated oocysts were less loosely located than those of other species. Other species known to infect fishes of the genera *Gobius*, *Neogobius* and *Proterorhynchus* (*Eimeria gobii*, *E. glossogobii*, *E. variabilis*, *E. credintsi*, *E. marmorati*, *E. daviesae*) and *Goussia kessleri* have smaller oocysts and leave the fish in the sporulated stage.

Discussion

Fish collections made between 1989 and 2004 in order to study the parasite fauna of gobiid fishes in the Danube River upstream from Budapest also furnished data on the spread and abundance of the newcomer goby species in the given Danube reaches. Data obtained in the first part of this study as well as in previous studies (Molnár, 1996) strongly suggested the dominance of the tubenose goby at that time, although Erős and Guti (1997) collected some specimens of the bighead goby in this part of the Danube. Further collections indicated that the number of tubenose gobies decreased continuously and that by 2004 no specimens were found in the catchment basin. Increased numbers of river goby and round goby were recorded in 2004, when, in addition to the drastically reduced population of the tubenose goby, a relative decrease in the prevalence of the bighead goby was also recorded. The appearance and expansion of the river goby and round goby were not unexpected, as Ahnelt et al. (1998); Holčík et al. (2003) and Corcum et al. (2004) had already reported their rapid spread. However, the intensive increase in their popu-

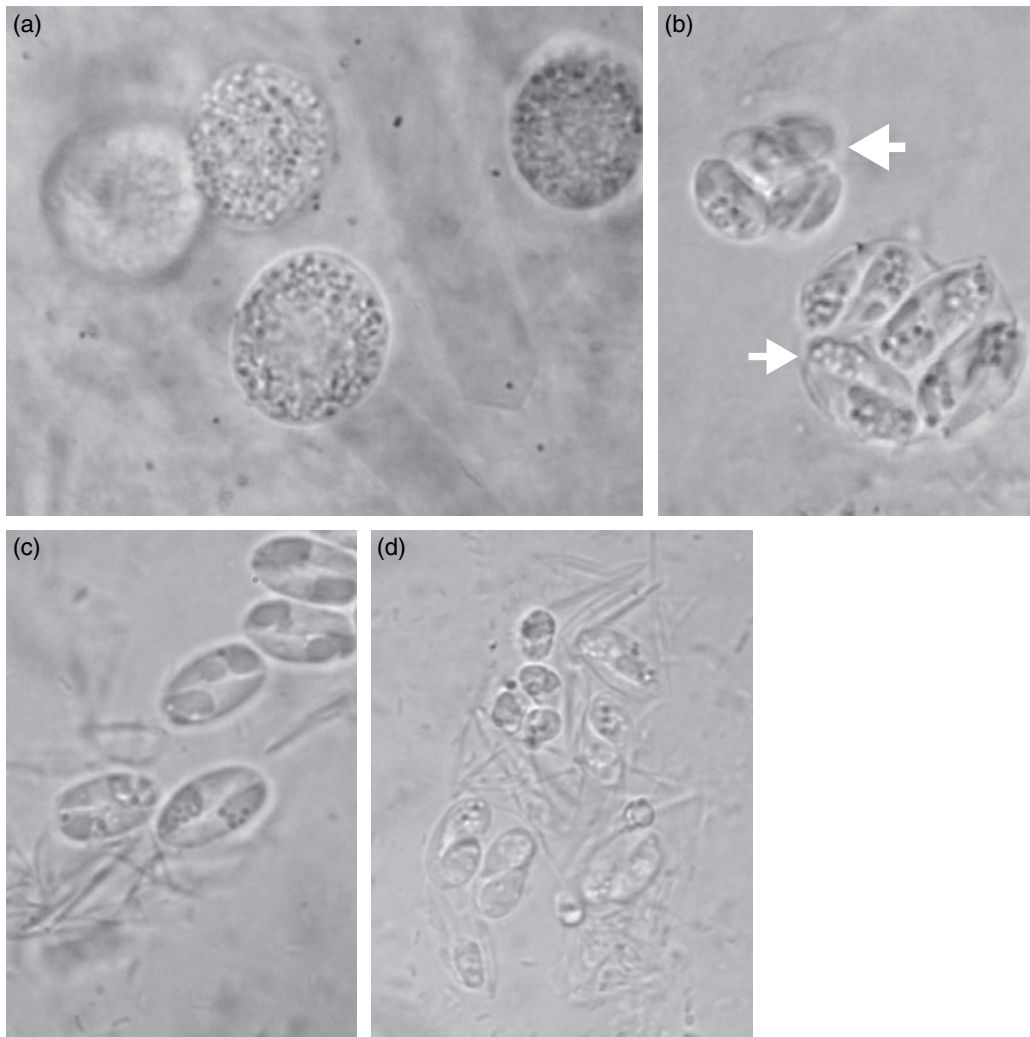


Fig. 3. Free *Goussia szekelyi* oocysts in the gut of *Neogobius melanostomus*. (a) Unsporulated oocysts. $\times 1000$; (b) Sporulated oocysts. The larger (arrow) is a *G. szekelyi* oocyst, the smaller (arrowhead) is a *G. kessleri* oocyst. Granules of the sporocyst residuum are located above the blunted ends of the banana-shaped sporozoites in *G. szekelyi* sporocysts. $\times 1500$. (c) Sporocysts released from the ruptured old oocysts. The number of residual granules decreased, a large refractile body is seen at the blunted end of sporozoites. $\times 1500$. (d) Moribund sporocysts. Sporozoites in sporocysts become pear shaped and finally round up. $\times 1500$

lation and the fact that they had become one of the most common fish species in the Danube, was surprising. The invasion mechanism of the river goby is especially interesting; this fish was recorded in Lake Balaton in 1971 (Bíró, 1972), and some specimens were collected in the Danube (Pintér, 1989). Although the northern invasion of gobies in Europe and their transcontinental expansion can be explained by their transfer in ballast water of ships or by the increase in the mean water temperature of rivers (Ahnelt et al., 1998; Corcum et al., 2004), such a rapid change of the fish fauna is unusual. It is highly likely that a marked decrease in the endemic tubenose goby population will also occur in other reaches of the Danube. The rapid decrease of the tubenose goby stock can be explained both by the expansion and the predacious nature of the newcomers. This latter possibility is supported by dissections performed during this study, which revealed semi-digested gobies or typical goby scales in the gut of large gobies.

The parasite fauna of gobies is relatively well studied. The majority of the registered species, however, belong to the less specific ubiquitous species (Bykhovskaya-Pavlovskaya et al., 1962; Naidenova, 1974). In the Czech Republic, Koubková and Baruš (2000) found that migrating gobies were infected by

the most common parasites also infecting the native fishes. Similar results were obtained in North America by Muzzal et al. (1995), Pronin et al. (1997) and Camp et al. (1999) who, in addition to helminths equally common in America and Europe, registered only a few typical North American parasites of a wide host range in the introduced tubenose goby and round goby. An exception was the species *Sphaeromyxa sevastopoli* Naidenova, 1970 (Myxosporea) known in the Black Sea region and also detected by Pronin et al. (1998) in the gallbladder of both tubenose gobies and round gobies in the St Clair River, Michigan.

The results obtained in this survey show that migrating gobies can transmit some of their parasites to their new biotopes, but that they can also be infected by ubiquitous parasites common in their new habitat. The parasite fauna of the three *Neogobius* species in the examined reaches of the Danube River proved to be poor: during the survey of 214 specimens of these three species, only 10 parasite species were recorded. Of the specific parasites, coccidia seem to be the most characteristic, infecting only the *Neogobius* species. Based on the morphology of the collected oocysts it seems that these three species have common eimeriid parasites and that they

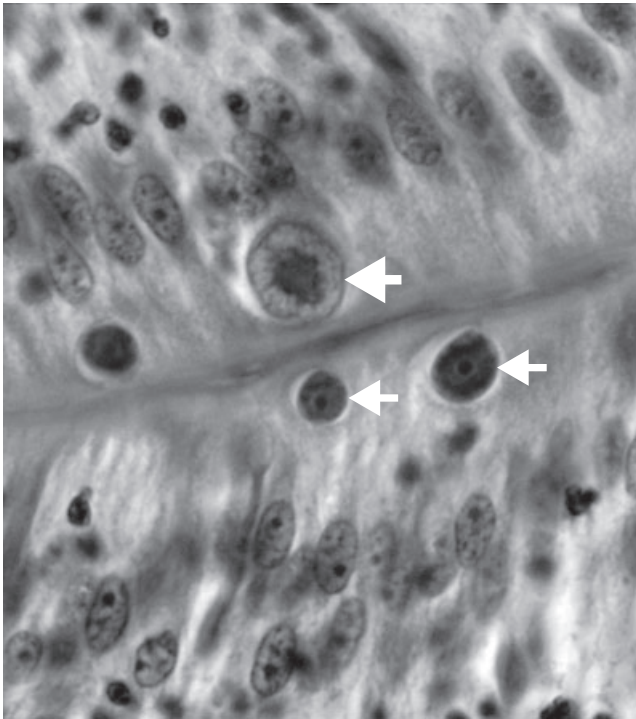


Fig. 4. Histological section of the intestine of *Neogobius melanostomus*. Haematoxylin and eosin (H. & E.) $\times 1000$. Young trophozoites (arrows) and a mature macrogamont (arrowhead) are located in the apical plasm of the enterocytes

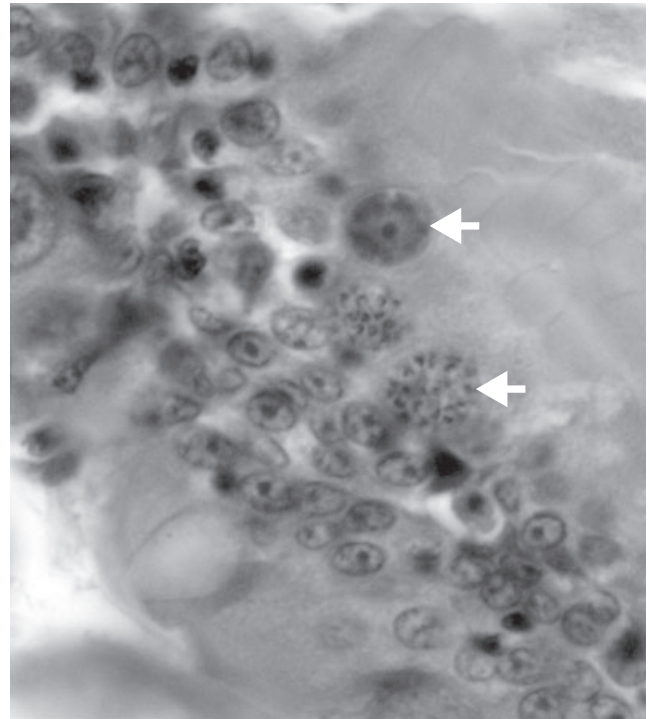


Fig. 6. Histological sections of the intestine of *Neogobius melanostomus*. Haematoxylin and eosin (H. & E.) $\times 1000$. Young microgamonts (arrows) with dot-like microgametes are located in the enterocytes

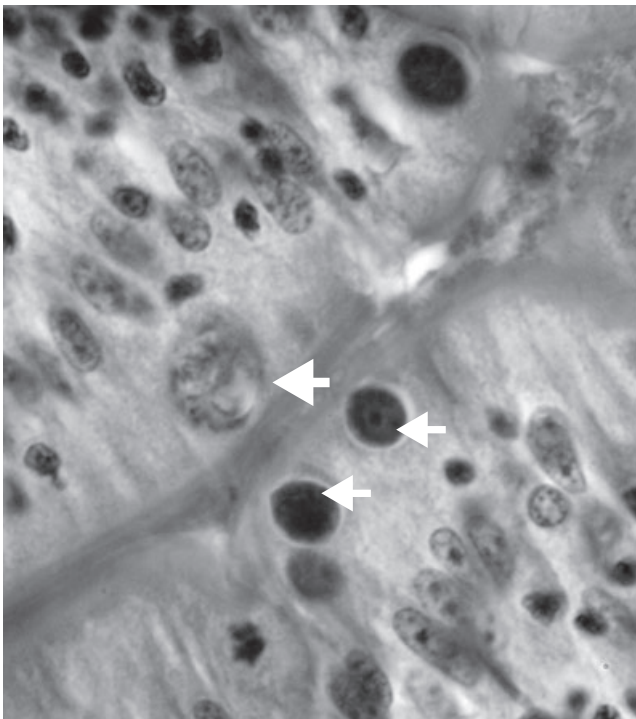


Fig. 5. Histological section of the intestine of *Neogobius melanostomus*. Haematoxylin and eosin (H. & E.) $\times 1000$. Young trophozoites (arrows) and a mature microgamont (arrowhead) containing comma-shaped microgametes are located in the apical plasm of the enterocytes

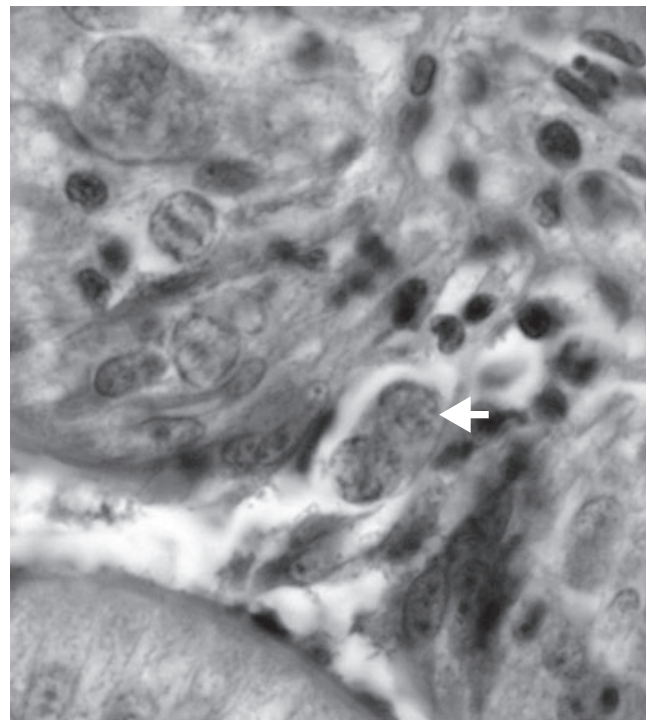


Fig. 7. Histological sections of the intestine of *Neogobius melanostomus*. Haematoxylin and eosin (H. & E.) $\times 1000$. Damaged epithelium above the macrogamonts (arrow)

can be infected by *Eimeria daviesae*, *Goussia kessleri* and, in all likelihood, by the new species *G. szekelyi* n. sp. At the same time, coccidia of the tubenose goby, belonging to the genus *Proterorhinus*, do not seem to infect these fishes.

Neogobius spp. can also be infected by a wide range of parasites. Metacercariae of the trematode *Metagonimus yokogawai*, acanthella stages of *Pomphorhynchus laevis* and imago stages of *Nicolla skrjabini* were recorded frequently. These species infect practically all Danube fishes (Vojtek, 1959;

Molnár, 1969; Žitnan, 1969). The occurrence of *Apatemon cobitidis* in *Neogobius* spp. could also be expected, as these larvae commonly infected the tubenose goby (Vojtek, 1964). Vojtek (1976) supposed that within the *A. cobitidis* species there were two subspecies, namely *A. cobitidis proterorhini*, which infected the tubenose goby, and *A. cobitidis cobitidis*, which was a parasite of the stone loach [*Barbatula barbatula* (L.)] and the bullhead (*Cottus gobio* L.).

Acknowledgements

The study was supported by the Hungarian Scientific Research Fund (OTKA, project no. T.031755). The author thanks Dr Csaba Székely for collecting fishes and for his help in preparing microscopic photos, and Ms. Györgyi Pataki for preparing the line drawing. The author is grateful to Dr S.S. Desser for kindly reading the manuscript and for his suggestions.

References

- Ahnelt, H.; Banarescu, P.; Spolwind, R.; Harka, A.; Waidbacher, H., 1998: Occurrence and distribution of three gobiid species (Pisces, Gobiidae) in the middle and upper Danube region – examples of different dispersal patterns? *Biologia* **53**, 665–678.
- Bíró, P., 1972: *Neogobius fluviatilis* in Lake Balaton – a Ponto-Caspian goby new to the fauna of Central Europe. *J. Fish Biol.* **4**, 249–254.
- Bykhovskaya-Pavlovskaya, I. E.; Gusev, A. V.; Dubinina, M. N.; Izyumova, N. A.; Smirnova, T. S.; Sokolovskaya, I. L.; Shtein, F. G.; Shulman, S. S.; Epstein, V. M., 1962: Key to the parasites of freshwater fish of the USSR. Publishing House Akademii Nauk, Moscow–Leningrad, 776 p. (in Russian).
- Camp, J. W.; Blaney, L. M.; Barnes, D. K., 1999: Helminths of the round goby, *Neogobius melanostomus* (Perciformes: Gobiidae), from southern Lake Michigan, Indiana. *J. Helminthol. Soc. Wash.* **66**, 70–72.
- Corcum, L. D.; Sapota, M. R.; Skora, K. E., 2004: The round goby, *Neogobius melanostomus*, a fish invader on both sides of the Atlantic Ocean. *Biologic. Invas.* **6**, 173–181.
- Dyková, J.; Lom, J., 1983: Fish coccidia: an annotated list of described species. *Folia Parasitol.* **30**, 193–208.
- Erős, T.; Guti, G., 1997: The first record of *Neogobius kessleri* Günther, 1861 in the Hungarian section of the Danube. *Halászat* **90**, 83–84 (in Hungarian).
- Guti, G., 1999: *Neogobius syrman* (Nordmann, 1840) in the Hungarian section of the Danube. *Halászat* **92**, 30–33 (in Hungarian).
- Guti, G.; Erős, T.; Szalóky, Z.; Tóth, B., 2003: Round goby, *Neogobius melanostomus* (Pallas, 1811) in the Hungarian section of the Danube. *Halászat* **96**, 116–119. (in Hungarian).
- Holčík, J.; Stranai, I.; Andreji, J., 2003: The further advance of *Neogobius fluviatilis* (Pallas, 1814) (Pisces, Gobiidae) upstream of the Danube. *Biologia* **58**, 967–973.
- Jude, D. J.; Reider, R. H.; Smith, G. R., 1992: Establishment of Gobiidae in the Great-Lakes Basin. *Can. J. Fisher. Aquat. Sci.* **49**, 416–421.
- Koubková, B.; Baruš V., 2000: Metazoan parasites of the recently established tubenose goby (*Proterorhinus marmoratus*: Gobiidae) population from the south Moravian reservoir, Czech Republic. *Helminthologia* **37**, 89–95.
- Molnár, K., 1969: Beiträge zur Kenntnis der Fischparasitenfauna Ungarns IV. *Parasitol. Hung.* **2**, 119–136.
- Molnár, K., 1996: Eimerian infection in the gut of the tube-nosed goby *Proterorhinus marmoratus* (Pallas) of the River Danube. *Syst. Parasitol.* **34**, 43–48.
- Molnár, K., 2000: Two new coccidia, a *Goussia* and an *Eimeria* spp. from the gut of Kessler's goby (*Gobius kessleri* Günther) in the River Danube. *Acta Protozool.* **39**, 223–229.
- Molnár, K.; Baska, F., 1998: Remarks on the occurrence of some fish species in Danube in connection with the mass occurrence of Kessler's goby, *Neogobius kessleri*. *Halászat* **91**, 94–96 (in Hungarian).
- Moshu, A. B., 1992: New species of coccidia (Protista: Apicomplexa, Eimeriidae) from fishes of the Hidigichki Water Reservoir (Moldova). *Bul. Acad. Stiinte Rep. Moldova* **4**, 56–62 (in Russian).
- Muzzal, P. M.; Peebles, C. R.; Thomas, M. V., 1995: Parasites of the round goby, *Neogobius melanostomus*. and tubenose goby, *Proterorhinus marmoratus* (Perciformes, Gobiidae), from the St. Clair River and Lake St. Clair, Michigan. *J. Helminthol. Soc. Wash.* **62**, 226–228.
- Naidenova, N. N., 1974: Parasite fauna of the family of Gobies of the Black and Azov seas. *Naukova Dumka, Kiev*. 182 p. (in Russian).
- Philips, E. C.; Washek, M. E.; Hertel, A. W.; Niebel, B. M., 2003: The round goby (*Neogobius melanostomus*) in Pennsylvania tributary streams of Lake Erie. *J. Great Lakes Res.* **29**, 34–40.
- Pintér, K., 1989: Fishes of Hungary. *Akadémiai Kiadó, Budapest*, 202 pp. (in Hungarian).
- Pronin, N. M.; Fleischer, G. W.; Baldanova, D. R.; Pronina, S. V., 1997: Parasites of the recently established round goby (*Neogobius melanostomus*) and tubenose goby (*Proterorhinus marmoratus*) (Cottidae) from the St. Clair River and Lake St. Clair, Michigan, USA. *Folia Parasitol.* **44**, 1–6.
- Sapota, M. R., 2004: The round goby (*Neogobius melanostomus*) in the Gulf of Gdansk – a species introduction into the Baltic Sea. *Hydrobiologia* **514**, 219–224.
- Vanderploeg, H. A.; Nalepa, T. F.; Jude, D. J.; Mills, E. L.; Holec, K. T.; Liebig, J. R.; Grigorovich, I. A.; Ojaveer, H., 2002: Dispersal and emerging ecological impacts of Ponto-Caspian species in the Laurentian Great Lakes. *J. Fisher. Aquat. Sci.* **59**, 1209–1228.
- Vojtek, J., 1959: Data to the knowledge of the helminthofauna of fish around Komarno. Publications of the Faculty of Science, University of Brno, Czechoslovakia, vol. 207, pp. 437–465 (in Czech).
- Vojtek, J., 1964: Zur Kenntnis der Entwicklungszyklus von *Apatemon cobitidis* (Linstow, 1890). *Z. Parasitenknd.* **24**, 578–599.
- Vojtek, J., 1976: Einige ökologische Aspekte des Studiums der Entwicklungszyklen der Trematoden. *Skripta Fac. Sci. Nat. Ujpe Brun. Biologia* **1**, 1–8.
- Žitnan, R., 1969: Zur Heminthenfauna der Fische in der Kleinen Donau. *Helminthologia* **10**, 313–320.

Author's address: Kálmán Molnár, Veterinary Medical Research Institute, Hungarian Academy of Sciences, H-1581 Budapest, PO Box 18, Hungary. E-mail: kalman@vmri.hu