

# Occurrence of *Atractolytocestus huronensis* Anthony, 1958 (Cestoda: Caryophyllaeidae), in Hungarian pond-farmed common carp

<sup>1</sup>G. Majoros, <sup>1</sup>Gy. Csaba and <sup>2</sup>K. Molnár

<sup>1</sup>Central Veterinary Institute, H-1581 Budapest 149, POB 2, Hungary; <sup>2</sup>Veterinary Medical Research Institute, Hungarian Academy of Sciences, H-1581 Budapest, POB 18, Hungary

## Summary

In 2001, a caryophyllidean tapeworm, *Atractolytocestus huronensis* was detected in the intestine of pond-farmed common carp in Hungary. Within two years the cestode spread throughout Hungary and its presence has been demonstrated in several pond farms. The parasite commonly occurred in the gut of market sized common carp imported from the Czech Republic. The cestode can infect some weeks old common carp fry and older age groups alike. *A. huronensis* specimens measuring 0.7–1.5 cm occurred in the most proximal segment of the common carp foregut, where they were firmly attached to the gut wall by their scolex. By its characteristically low number of testes *A. huronensis* is well distinguishable from the species *A. sagittatus* known from East Asia and from the Astrakhan territory of Russia.

## Introduction

Over a long period of time, economically important cestodes parasitising the gut of the European subspecies of common carp (*Cyprinus carpio carpio*) in adult form were represented solely by the species *Caryophyllaeus laticeps* (Pallas) (Schäperclaus, 1954). Later on, Russian authors (Bauer *et al.*, 1969) suggested that the common carp was also parasitised by a species well distinguishable from *C. laticeps*, i.e. *Caryophyllaeus fimbriceps* Annenkova-Chlopina. From the gut of the Far Eastern common carp subspecies (*Cyprinus carpio haematopterus*) another caryophyllidean cestode species, *Khawia sinensis* Hsü was known, the European appearance of which was reported by Kulakovskaya and Krotas (1961). *Khawia sinensis* soon became widespread in the European common carp stocks (Mattheis and Spangenberg, 1974; Panczyk and Zelazny, 1974; Scholz, 1991), driving out the native *C.*

*fimbriceps* species from the pond farms. The appearance of this parasite in Hungary and its differentiation from *C. fimbriceps* were reported by Molnár and Buza (1975) as well as Murai and Molnár (1975). Until quite recently, the cosmopolitan species *Bothriocephalus acheilognathi* Yamaguti, brought into Europe by introduction of the grasscarp (*Ctenopharyngodon idellus*), was the cestode most commonly found in the gut of common carp in Hungary, in addition to the common carp specific *K. sinensis* (Malevitzkaya, 1958; Musselius, 1962).

This paper reports that a new caryophyllidean cestode hitherto unknown in Europe has appeared in the Hungarian pond-farmed common carp stocks, which causes intensive infection in some ponds and can be identified anatomically with the cestode *Atractolytocestus huronensis* Anthony, 1958 described in North America.

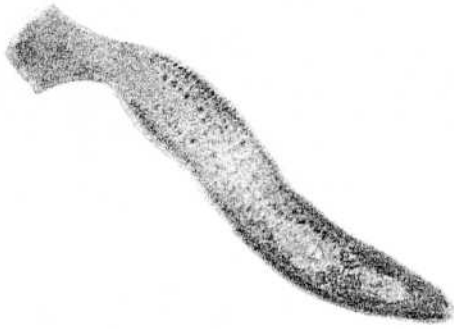


Fig. 1. *Atractolytocestus huronensis* Anthony, 1958 from *Cyprinus carpio*. A fixed specimen stained with carmine. x 5.

### Materials and methods

Veterinarians of the Central Veterinary Institute regularly screen the fish stocks of large pond farms for diseases every year. They first noticed the tiny cestodes in common carp specimens of a pond farm located on the Great Hungarian Plain on the occasion of an on-site fish dissection. Subsequently the specialists looked for such cestodes in the gut of all pond-farm fish specimens submitted for laboratory examinations.

The cestodes found were placed into 0.65% isotonic saline solution after collection, freed from the adhering mucus by gentle shaking, and measured. Some of the cestode specimens were rendered transparent with lactic acid during slight compression between slides while others with methyl salicylate after dehydration, and then examined in toto. Some of the cestodes were fixed in 70% ethanol solution or 10% hot formalin solution, stained with borax carmine or alum-carmine and embedded into Canada balsam without sectioning after dehydration. Five specimens were fixed under coverslip in Bouin's solution in slightly flattened condition for 4 hours,

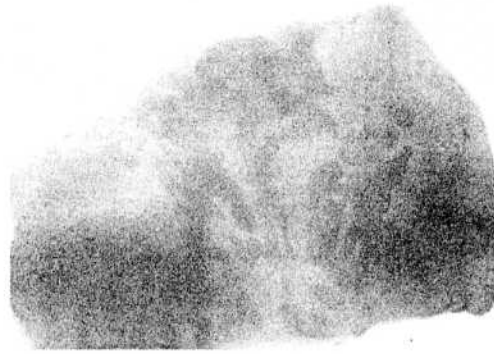


Fig. 2. Native *Atractolytocestus huronensis* Anthony, 1958 cestodes in the foregut of a common carp (*Cyprinus carpio*). x 5.

then embedded in paraffin, and sectioned longitudinally. The 5–8  $\mu\text{m}$  thick sections were stained with haematoxylin and eosin solutions. The cestode specimens examined in their entirety and the sections were photographed with a digital camera mounted on an Olympus BH2 microscope.

### Results

On 28 July 2001 unknown small caryophyllidean tapeworms were found in the gut of two-summer common carp submitted for routine examination from an Eastern Hungarian pond farm (Figs 1 and 2). On detailed examination, on the basis of their morphological characteristics these cestodes could be identified with the species *Atractolytocestus huronensis* Anthony, 1958. In the following months further infected fish were found in the above fish farm and also a farm in the western part of Hungary (Table 1).

In the spring of 2002, specimens of this parasite were detected in the same stock of the previous farms as well as from the overwintered fry stock of further two farms. The parasite was detected on several occa-

	Date of exam	Age of fish	No fish	Fish farms	No. inf. spec.	Prev. %	Intensity	Remarks
1	2001 July	2+	6	I EH	6	100	4-20	
2	August	1+	100	I EH	11	11	1-22	
3	October	1+	100	II WH	100	100	4-31	
4	2002 February to June	3+	108	CZR	81	75	1-42	
5	April	2+	20	II WH	8	40	1-6	
6	May	2+	10	III WH	7	70	4-11	
7	May	2+	10	IV EH	4	40	1-4	
8	July	6 weeks	20	I EH	18	90	1-16	Pond I
9	July	6 weeks	100	I EH	0	0	0	Ponds II to VI
10	July	6 weeks	20	II WH	14	70	1-32	Pond I
11	July	6 weeks	20	II WH	3	15	1-30	Pond II
12	July	6 weeks	20	II WH	0	0	0	Pond III

Table 1. Occurrence of *A. huronensis* in common carp (*Cyprinus carpio*) during veterinary screening in 2001 and 2002. EH = East Hungary, WH = West Hungary, CZR = Imported food fish from the Czech Republic

sions in market sized common carp imported from the Czech Republic and not placed out into ponds.

Infection of the fry was first detected in 1.5-month-old common carp in mid-July 2002. In the intestine of these fish mature *A. huronensis* specimens not yet containing eggs were detected. Among the fry, infection was usually found in the biggest individuals. Among the 534 fish examined for *Atractolytocestus* infection 252 specimens (47 %) proved to be infected during investigations. The prevalence of infection varied by ponds within a given fish farm. During the fishing-off in the autumn of 2002, *A. huronensis* was detected in 11 other fish farms located in different geographic regions of Hungary.

During the routine diagnostic examination of common carp it was a conspicuous finding that *Khawia sinensis* and *Bothriocephalus acheilognathi* infection, which had been commonly diagnosed in earlier years, was detected much less often in 2002. About 3% of the examined common carp fry were infected

with *K. sinensis* and 7% with *B. acheilognathi*. These two cestode species could only exceptionally be detected in fish infected with *A. huronensis* specimens.

The cestodes could be detected exclusively in the gut of common carp (*Cyprinus carpio*), and were never found in the intestine of gibel carp (*Carassius auratus gibelio*), grasscarp (*Ctenopharyngodon idellus*) and silver carp (*Hypophthalmichthys molitrix*), even if these fish shared a pond with common carp specimens.

Major morphological data of the parasite identified as the species *Atractolytocestus huronensis* Anthony, 1958 are compiled in Table 2. Additional data are as follows:

Without any muscular contraction the scolex is arrowhead shaped (Fig. 3A). The live worm can stretch the scolex out to two or three times its original length or contract it into a broad roundish shape. Therefore, after fixation the scolex may have narrow spearhead or mushroom shape. The vitelline follicles start below

